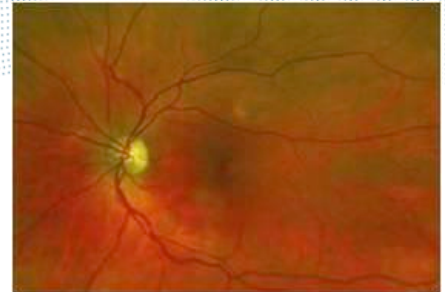


# Challenges in retinal imaging

**Jano van Hemert**  
jvanhemert@optos.com



Sunday, 3 March 13

1

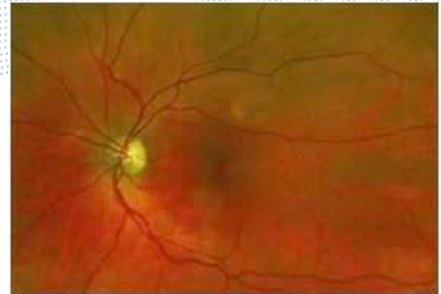
## Summary

Eye health care is a rapidly expanding market.

Retinal imaging requires constant technology innovation from physics and computer science.

Sunday, 3 March 13

2

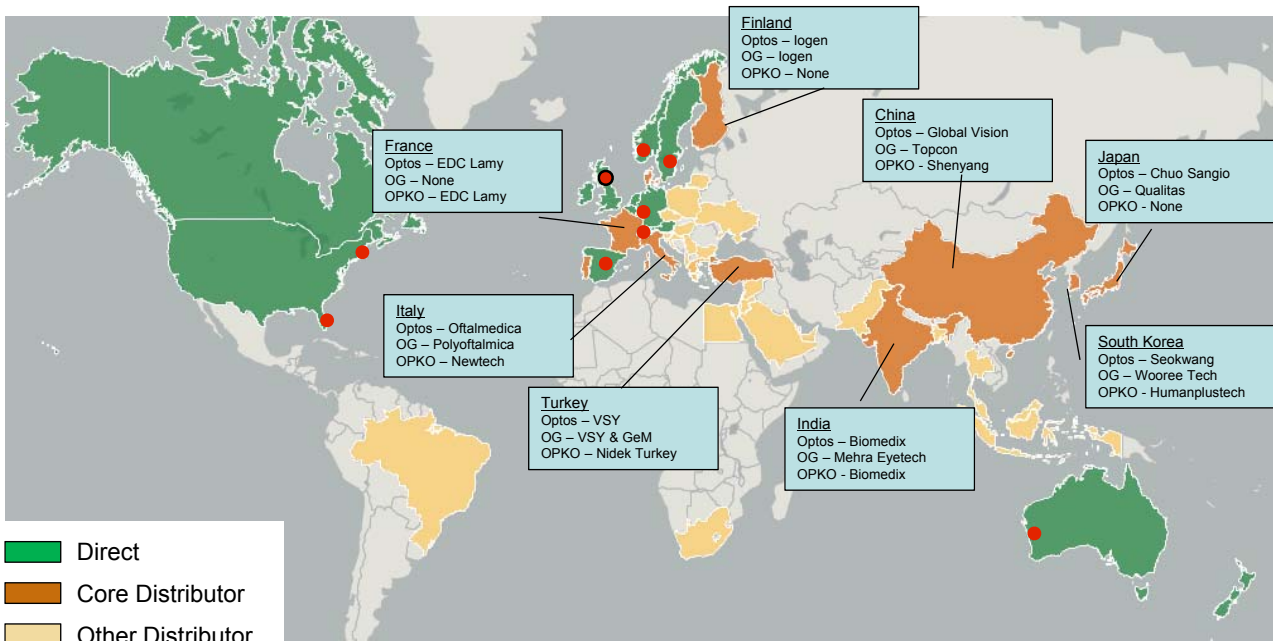


# Who, why, what and how?

Sunday, 3 March 13

3

## Who?



OPTS 22 Feb 2013 09:21:24 GMT

199.12 p ↑ +3.62 p +1.85%  
Volume 7,312

Optos revenue 2012

\$196.4m ↑ +53.1m +37%  
from 2011

Optos profits 2012

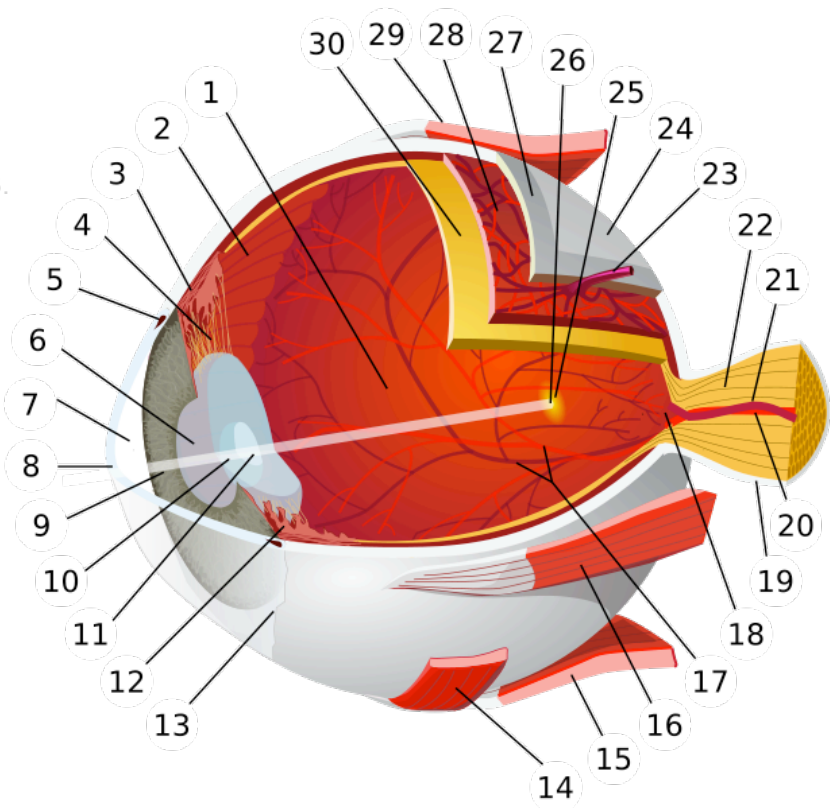
\$25.9m ↑ +0.8m +3%  
from 2011

Sunday, 3 March 13

4

# What?

1. vitreous body
2. ora serrata
3. ciliary muscle
4. ciliary zonules
5. canal of Schlemm
6. pupil
7. anterior chamber
8. cornea
9. iris
10. lens cortex
11. lens nucleus
12. ciliary process
13. conjunctiva
14. inferior oblique muscle
15. inferior rectus muscle
16. medial rectus muscle
17. retinal arteries and veins
18. optic disc
19. dura mater
20. central retinal artery
21. central retinal vein
22. optic nerve
23. vorticosse vein
24. bulbar sheath
25. macula
26. fovea
27. sclera
28. choroid
29. superior rectus muscle
30. retina



Sunday, 3 March 13

5

# Why?

Diabetic retinopathy incidence in +40 year-old diabetics in the US is 28.5±4% [1].

The cost of diabetic retinopathy to the US is approximately \$500 million annually [2].

The demand for eye-care services in The Netherlands will increase by 200–300% between 2010 and 2020 [3].

[1] Zhang X, et al. JAMA. 2010 Aug 11;304(6):649-56.

[2] Javitt JC, et al. Diabetes Care. 1994;17(8):909-917

[3] Keunen JE, et al.. Ned Tijdschr Geneesk. 2011;155(41):A3461

Sunday, 3 March 13

6

# Why?



Normal vision



Diabetic retinopathy



Age-related macular degeneration



Retinal detachment

Sunday, 3 March 13

7

# How?



Sunday, 3 March 13

8



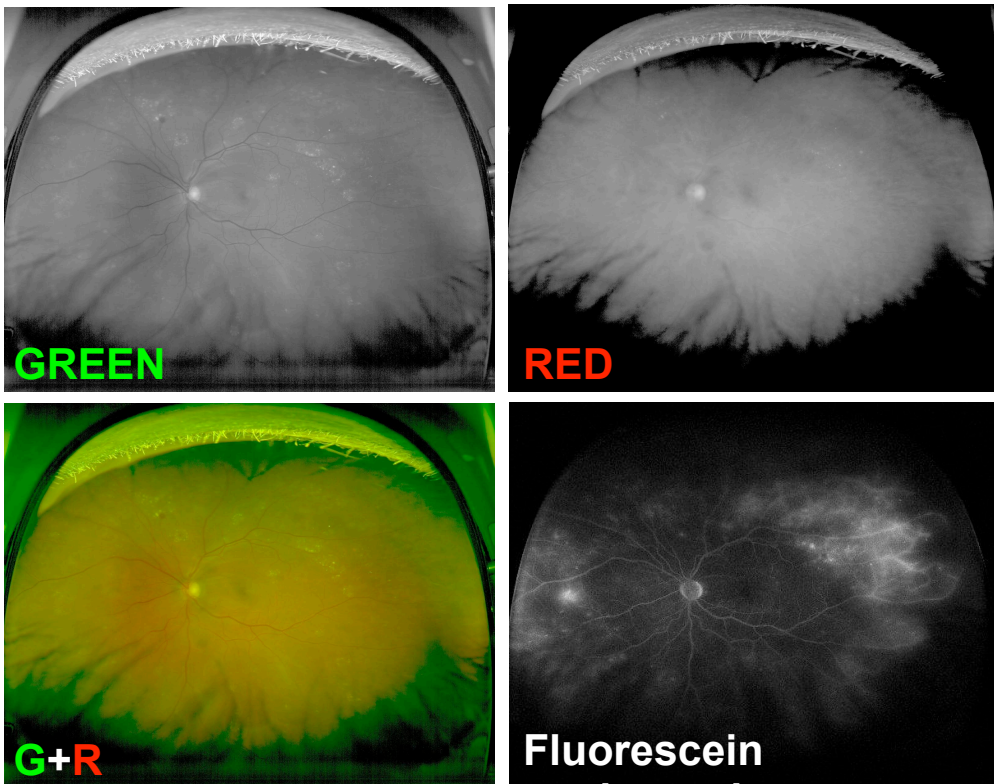
How?



Sunday, 3 March 13

9

How?



Sunday, 3 March 13

10

# Why?



Normal vision



Diabetic retinopathy



Age-related macular degeneration

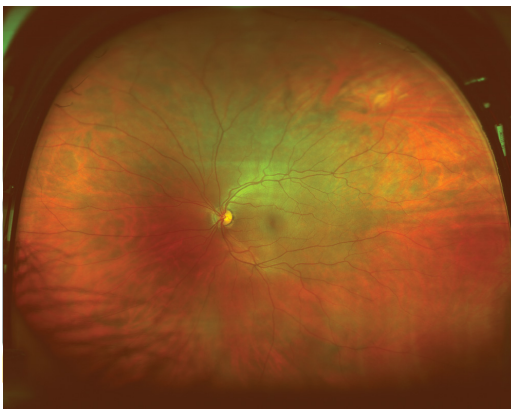


Retinal detachment

Sunday, 3 March 13

11

# Why?



Diabetic retinopathy



Age-related macular degeneration

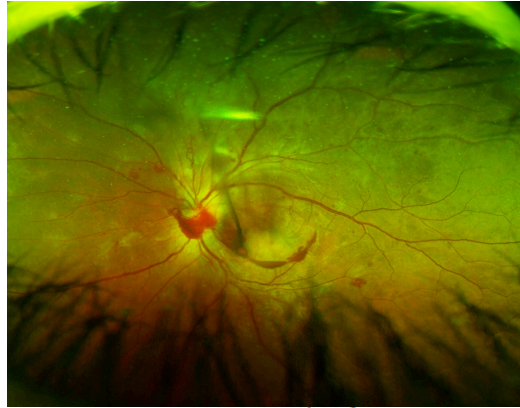
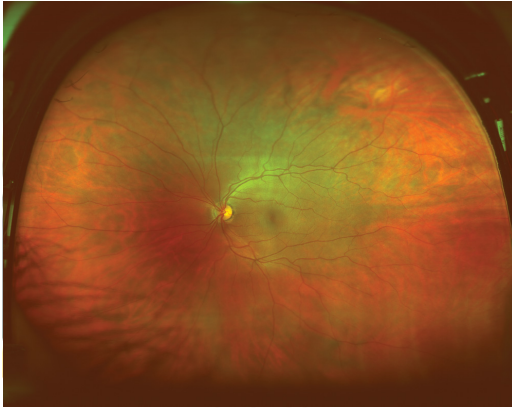


Retinal detachment

Sunday, 3 March 13

11

# Why?



Age-related macular degeneration

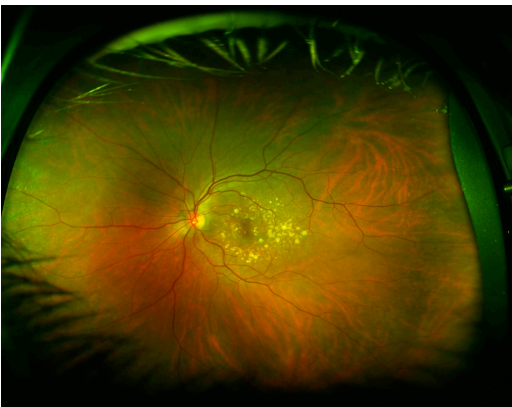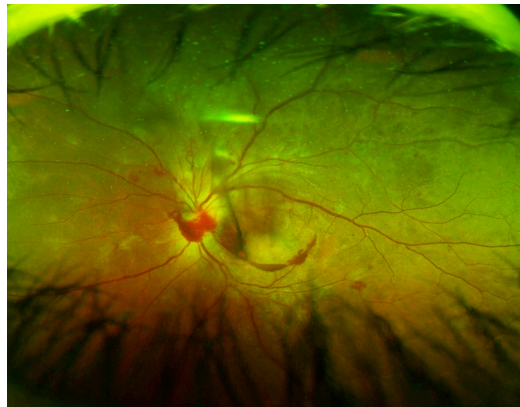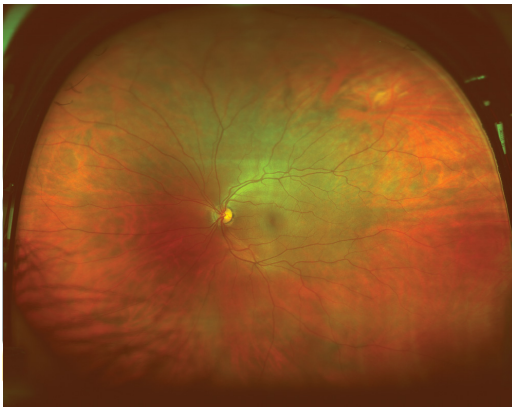


Retinal detachment

Sunday, 3 March 13

11

# Why?



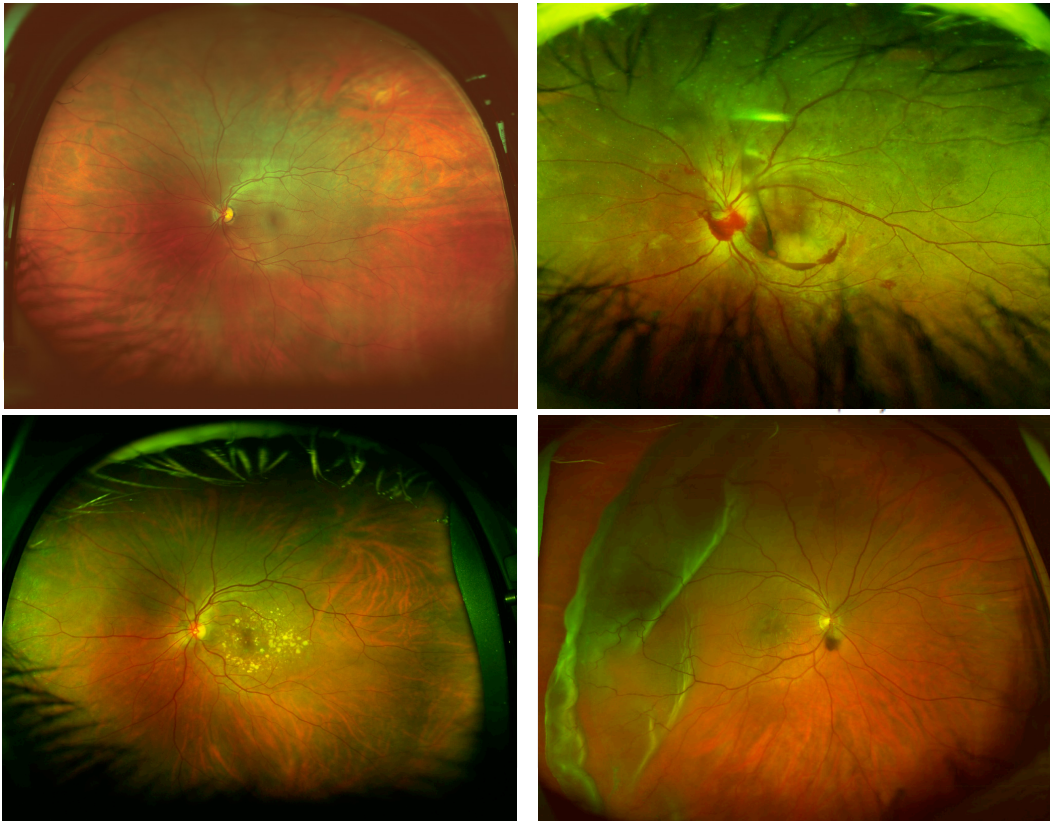
Retinal detachment

Sunday, 3 March 13

11



# Why?



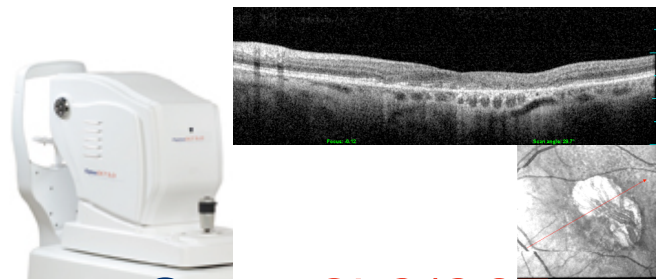
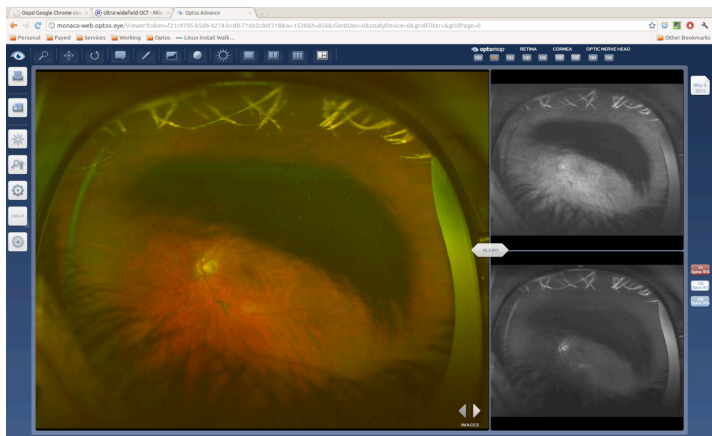

Sunday, 3 March 13

11

# How?

**Optos** ADVANCE™

*Daytona*



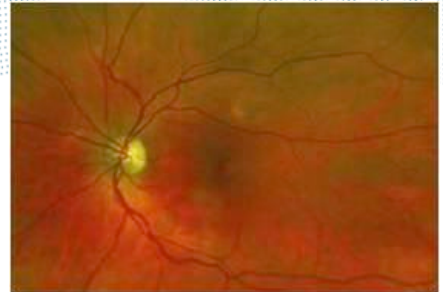
**Optos**SLO/OCT

Sunday, 3 March 13

12



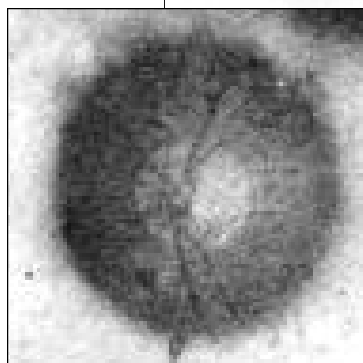
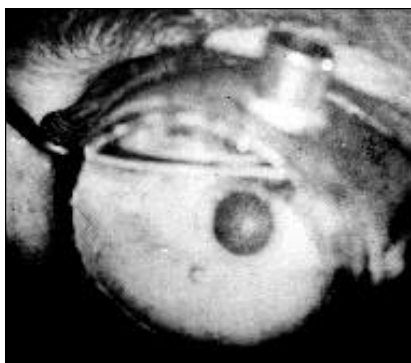
# Challenge: uptake of technology



Sunday, 3 March 13

13

## Birth of ophthalmic imaging



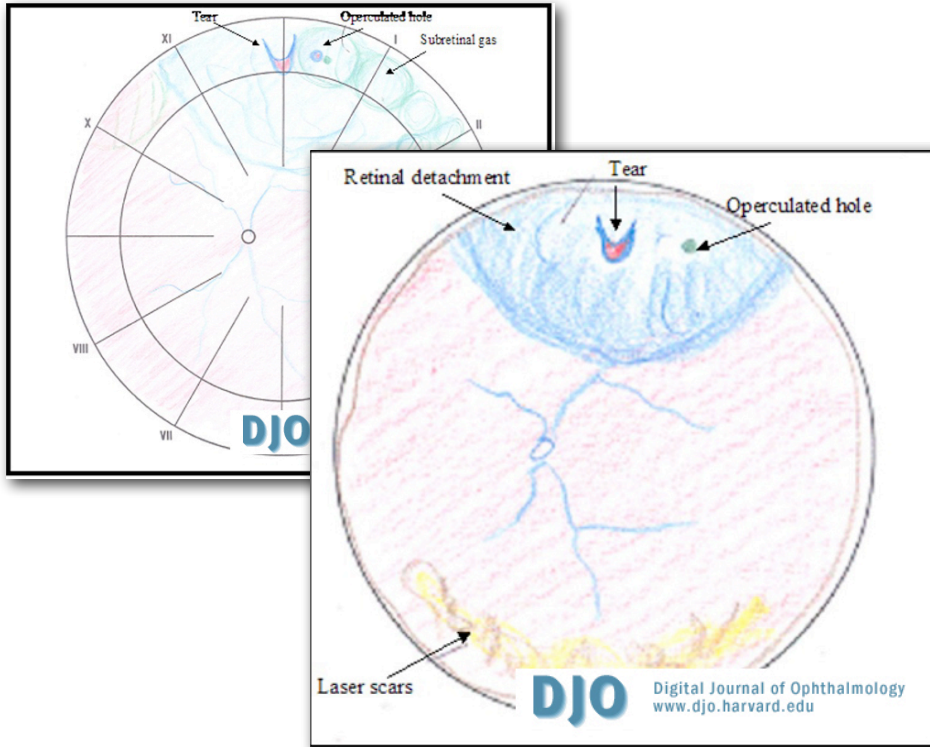
[1] Keeler CR. *Arch Ophthalmol.* 120(2):194-201.

[2] Gerloff O. *Ueber die Photographie des Augenhintergrundes.* *Klin Monatf Augenheil* 1891;29:397.

Sunday, 3 March 13

14

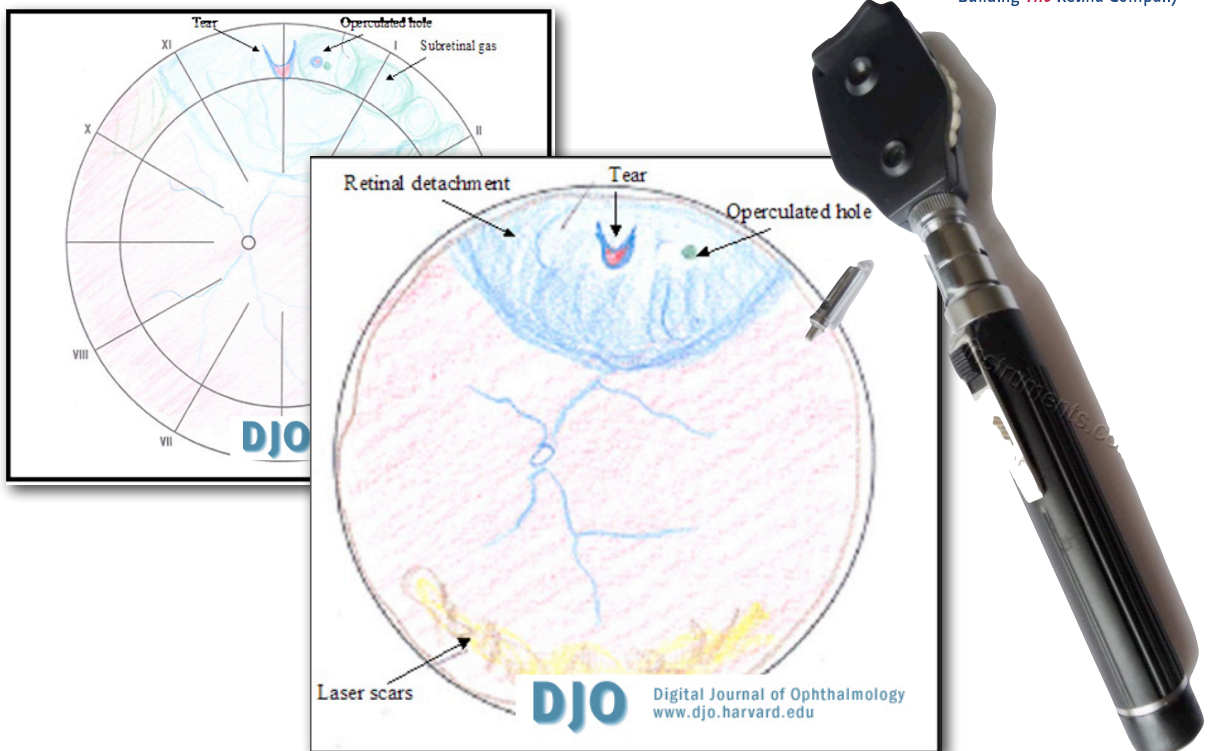
2004...



Sunday, 3 March 13

15

2004...



Sunday, 3 March 13

15

2004...

**DJO** Digital Journal of Ophthalmology  
www.djo.harvard.edu

**£50.99**  
*Buy it Now*  
or Best Offer  
+ £4.99 postage

Sunday, 3 March 13

15

2007...

<b>OD:</b>	<input checked="" type="checkbox"/> ni	External	<input checked="" type="checkbox"/> ni
	<input checked="" type="checkbox"/> ni	Lids/lashes	<input checked="" type="checkbox"/> ni
	<input checked="" type="checkbox"/> quiet	Conjunctiva	<input checked="" type="checkbox"/> quiet
	<input checked="" type="checkbox"/> clear	Cornea	<input checked="" type="checkbox"/> clear
	<input checked="" type="checkbox"/> D+Q	AC	<input checked="" type="checkbox"/> D+Q
	<input checked="" type="checkbox"/> round	Iris	<input checked="" type="checkbox"/> round
	<input checked="" type="checkbox"/> clear	Lens	<input checked="" type="checkbox"/> clear
	<input checked="" type="checkbox"/> IOL	Vitreous	<input checked="" type="checkbox"/> IOL
	<input checked="" type="checkbox"/> Clear		<input checked="" type="checkbox"/> Clear
<b>D</b> _____	<b>DFE</b> _____		
	<input checked="" type="checkbox"/> ni	macula	<input checked="" type="checkbox"/> ni
	<input checked="" type="checkbox"/> ni	periphery	<input checked="" type="checkbox"/> ni
	<input checked="" type="checkbox"/> ni caliber/distribution	vessels	<input checked="" type="checkbox"/> ni caliber/distribution

*Handwritten notes on the left: noplisy, step 2, step 3, RH*

Figure 1. A typical bedside indirect ophthalmoscopy examination drawing.

[1] Moshfeghi DM. Review of Ophthalmology. Nov. 2007

Sunday, 3 March 13

16

2007...

The present **gold standard** for ROP screening is binocular indirect ophthalmoscopy by an ophthalmologist experienced in the sequential changes of ROP. This recommendation comes from the Policy Statement on ROP screening from the **AAO, the Section on Ophthalmology from the American Academy of Pediatrics, and the American Association for Pediatric Ophthalmology and Strabismus.** ...

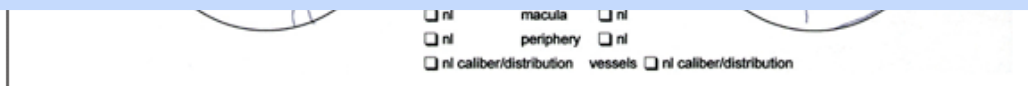
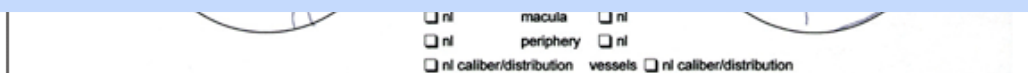


Figure 1. A typical bedside indirect ophthalmoscopy examination drawing.

[1] Moshfeghi DM. Review of Ophthalmology. Nov. 2007

2007...

The present **gold standard** for ROP screening is binocular indirect ophthalmoscopy by an ophthalmologist experienced in the sequential changes of ROP. This recommendation comes from the Policy Statement on ROP screening from the **AAO, the Section on Ophthalmology from the American Academy of Pediatrics, and the American Association for Pediatric Ophthalmology and Strabismus.** ...

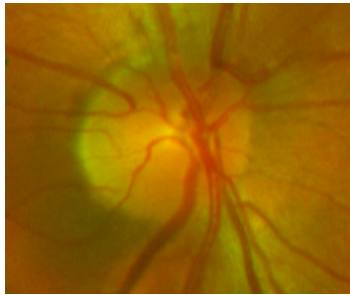


... Interestingly, there **has never been** a study validating the reproducibility or reliability of this technique. [1]

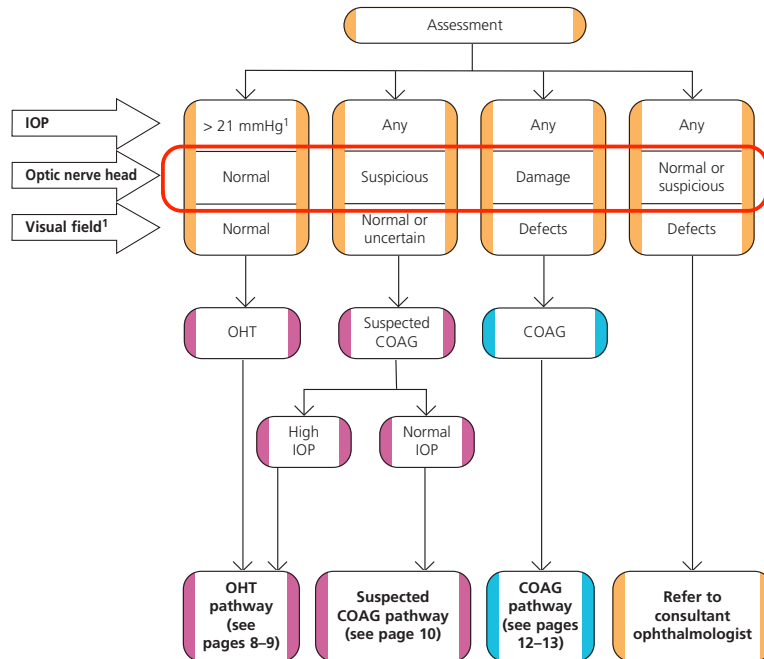
[1] Moshfeghi DM. Review of Ophthalmology. Nov. 2007



## Diagnosis of OHT, suspected COAG and COAG



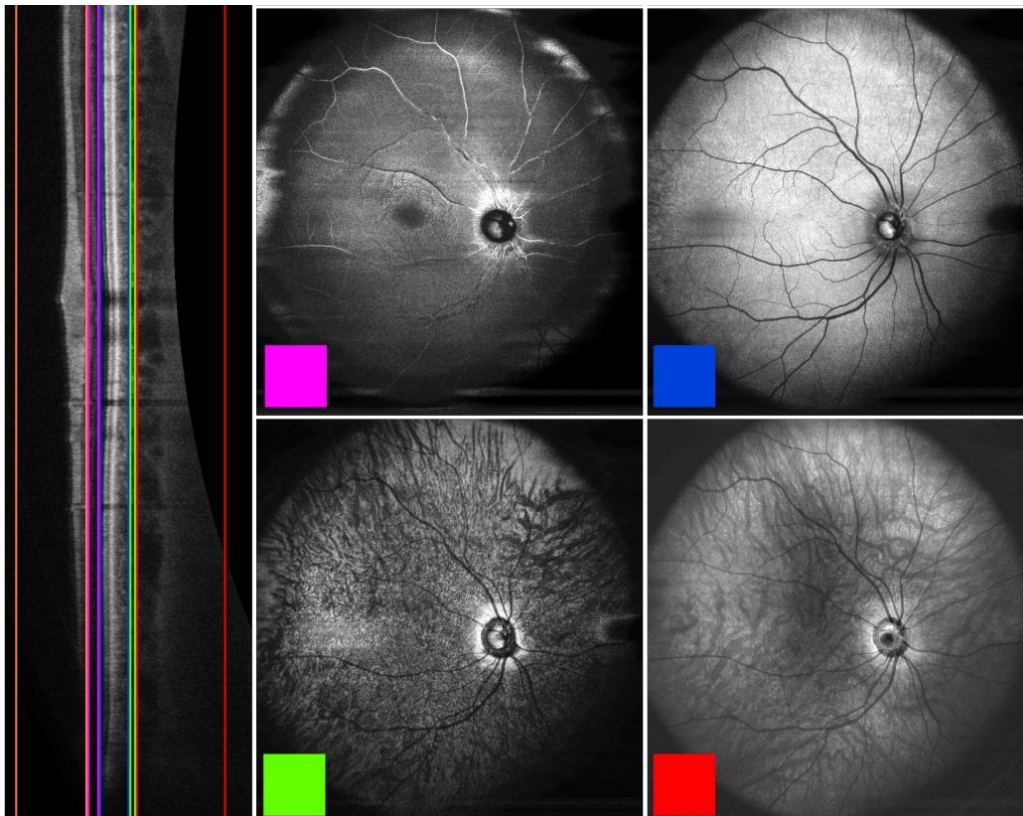
An Optic Nerve Head



[1] Diagnosis and management of chronic open angle glaucoma and ocular hypertension. NHS National Institute for Health and Clinical Excellence (NICE). Apr 2009.

## While we could have...

[1] Klein T. Optics Express. 19(4):3044-3062 (2011)



or perhaps...

**Mail**Online



Home | News | U.S. | Sport | TV&Showbiz | Femail | **Health** | Science | Money | RightMin

[Health Home](#) | [Health Directory](#) | [Health Boards](#) | [Diets](#) | [MyDish Recipe Finder](#)

## Done in the blink of an eye: New 30-second retina scan could prevent thousands of heart attacks every year

- High-def images will pick up signs of cardiac disease

By LUCY OSBORNE and JULIE-ANNE BARNES

PUBLISHED: 06:58, 10 April 2012 | UPDATED: 06:59, 10 April 2012

Sunday, 3 March 13

19

or perhaps...

**Mail**Online



Home | News | U.S. | Sport | TV&Showbiz | Femail | **Health** | Science | Money | RightMin

[Health Home](#) | [Health Directory](#) | [Health Boards](#) | [Diets](#) | [MyDish Recipe Finder](#)

## Done in the blink of an eye: New 30-second retina scan could prevent thousands of heart attacks every year

- High-def images will pick up signs of cardiac disease

By LUCY OSBORNE and JULIE-ANNE BARNES

PUBLISHED: 06:58, 10 April 2012 | UPDATED: 06:59, 10 April 2012

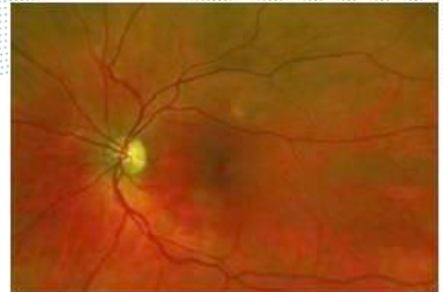
The test, pioneered by experts at the University of Edinburgh, will look at 1,000 patients with suspected heart disease. The study will prove whether scans can detect signs of heart disease, which can be difficult to diagnose.

Researchers will use specialist equipment on loan from Optos – an eye care company based in Dunfermline, Fife.

Sunday, 3 March 13

19

**Challenge:  
medical devices  
market**



Sunday, 3 March 13

20

**Market clearance in the USA**

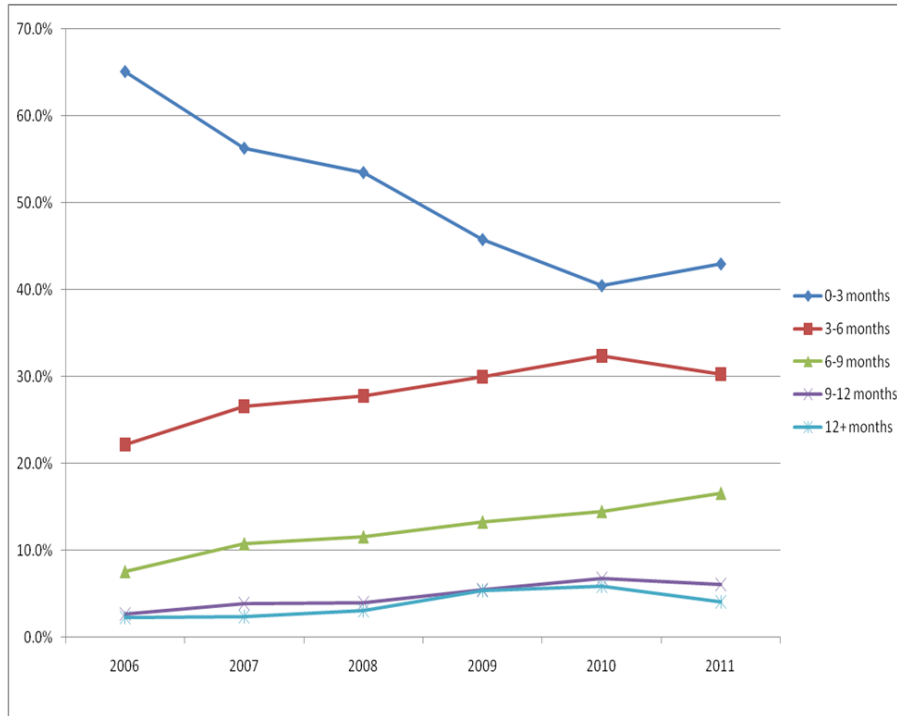
-  Special 510(k)
  -  Abbreviated 510(k)
  -  Traditional 510(k)
  -  Premarket Approval
- Classes I, II, III
- Class III



Sunday, 3 March 13

21

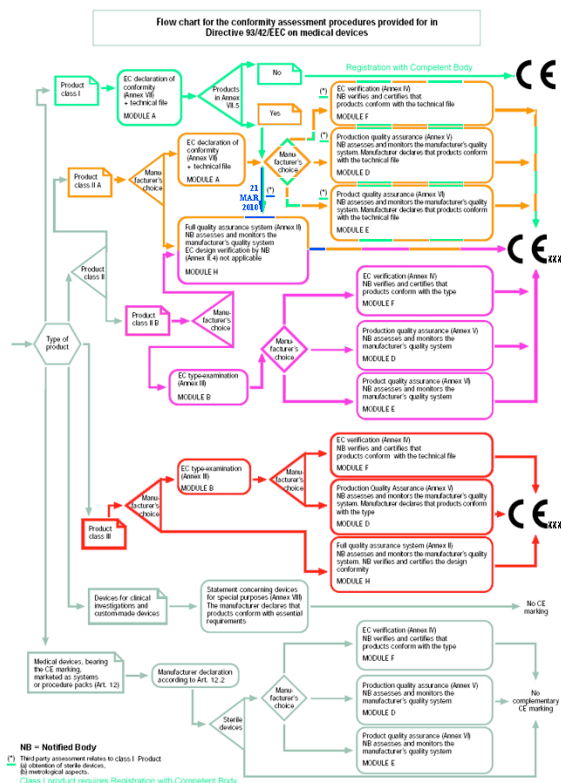
# Average time for 510(k) submissions to clear



**Average number of days to clearance:**  
 2006 – 97 days  
 2007 – 110 days  
 2008 – 118 days  
 2009 – 136 days  
 2010 – 146 days  
 2011 – 138 days

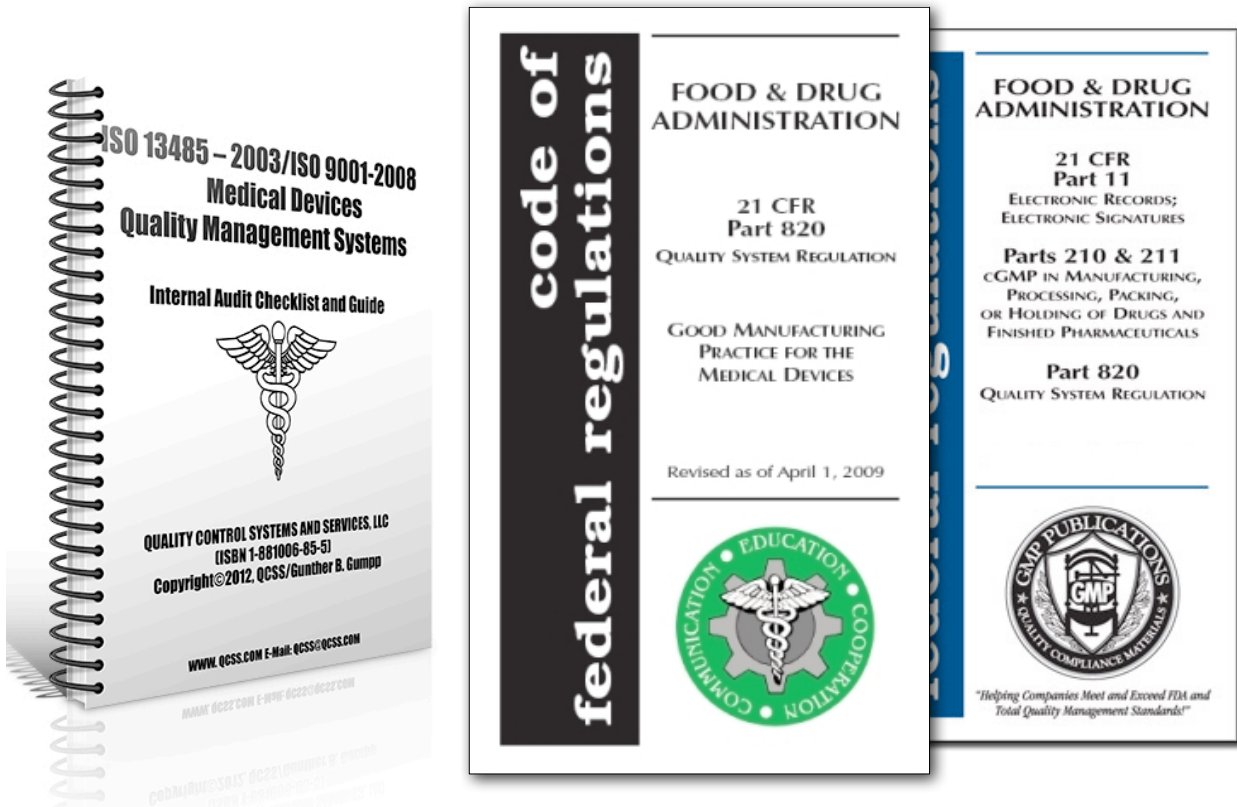
[1] Emergo Group. <http://www.emergogroup.com/research/fda-510k-review-times-research> 2013-01-31

## And so on...





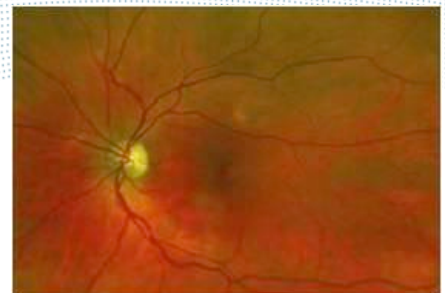
# Congratulations... now the bad news



Sunday, 3 March 13

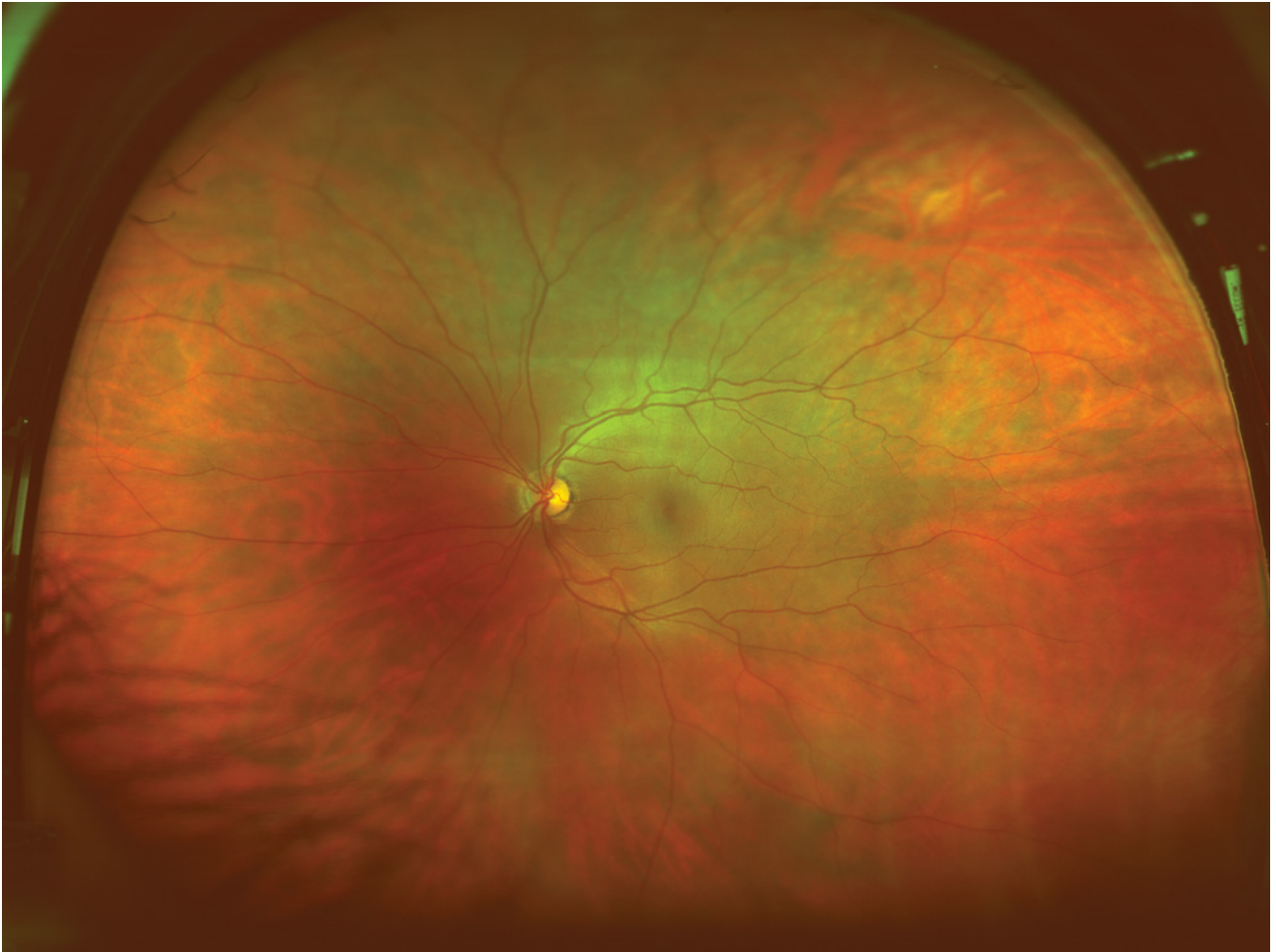
24

## Challenge: technology itself



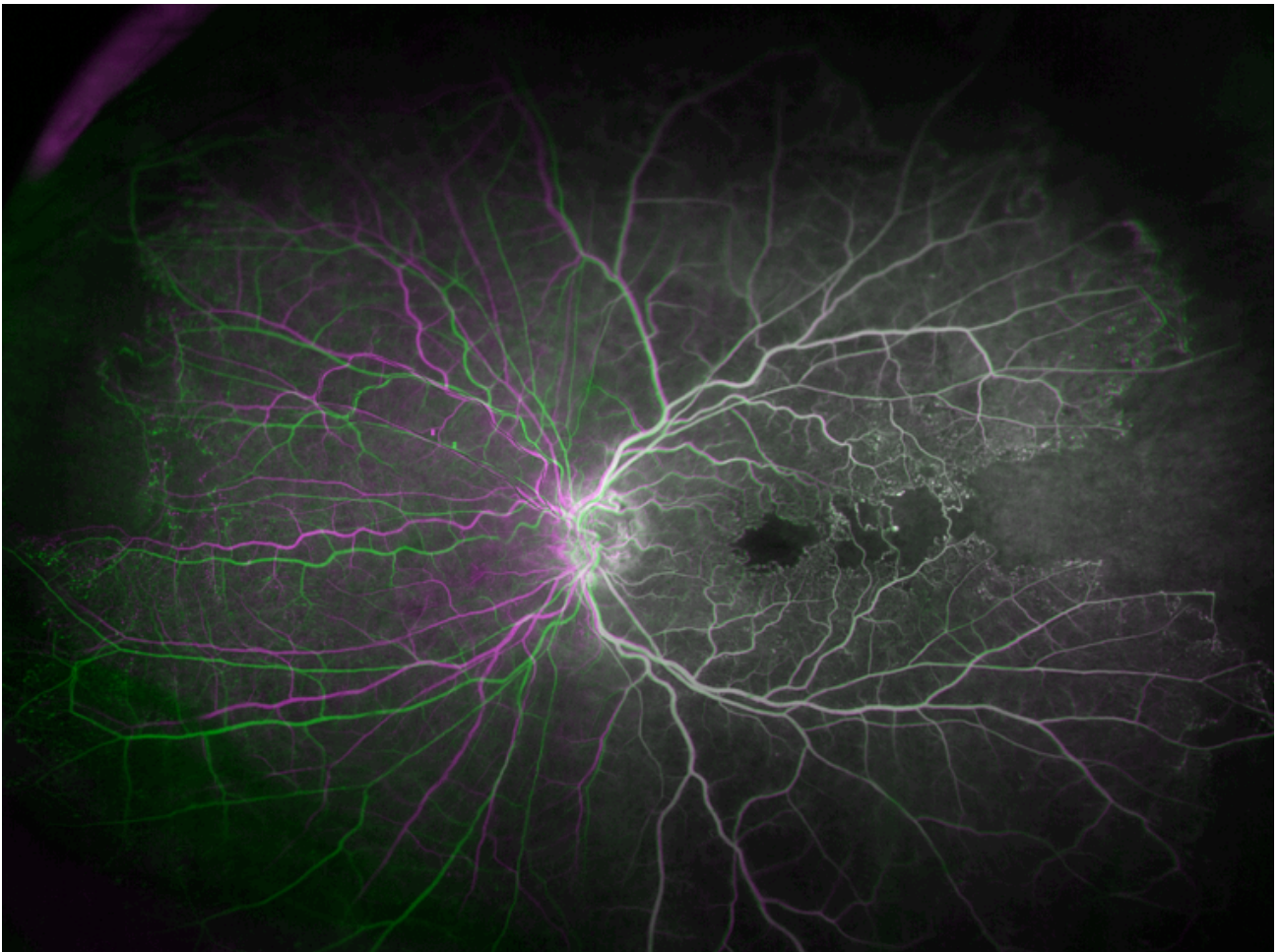
Sunday, 3 March 13

25



Sunday, 3 March 13

26

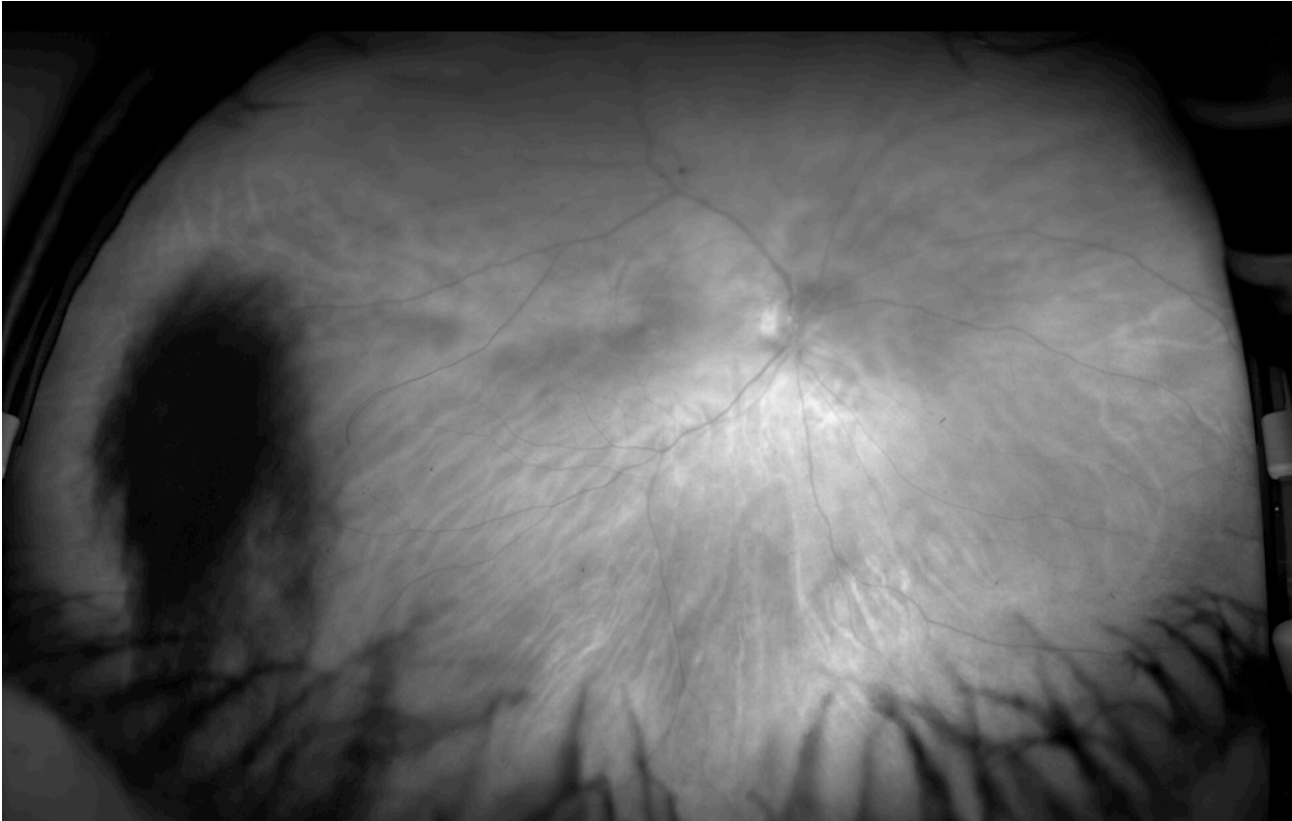


Sunday, 3 March 13

27

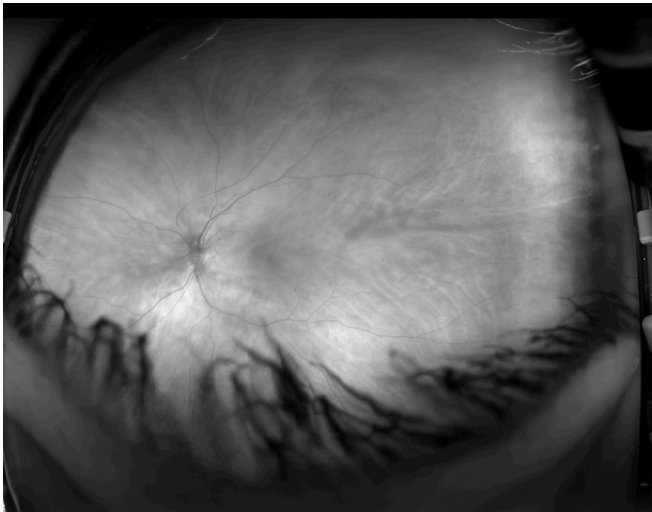
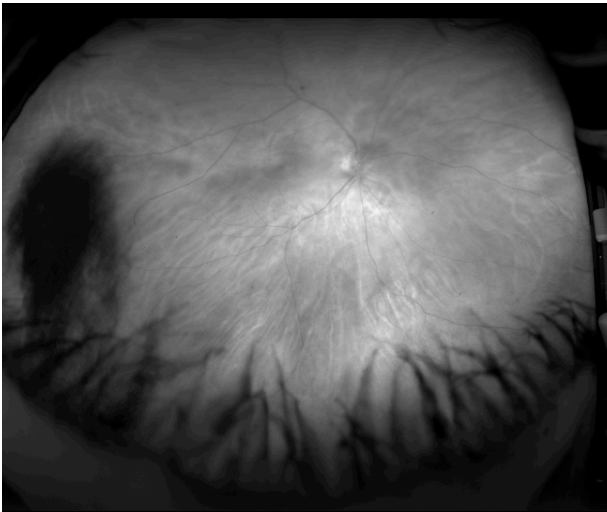


# Spot the problem



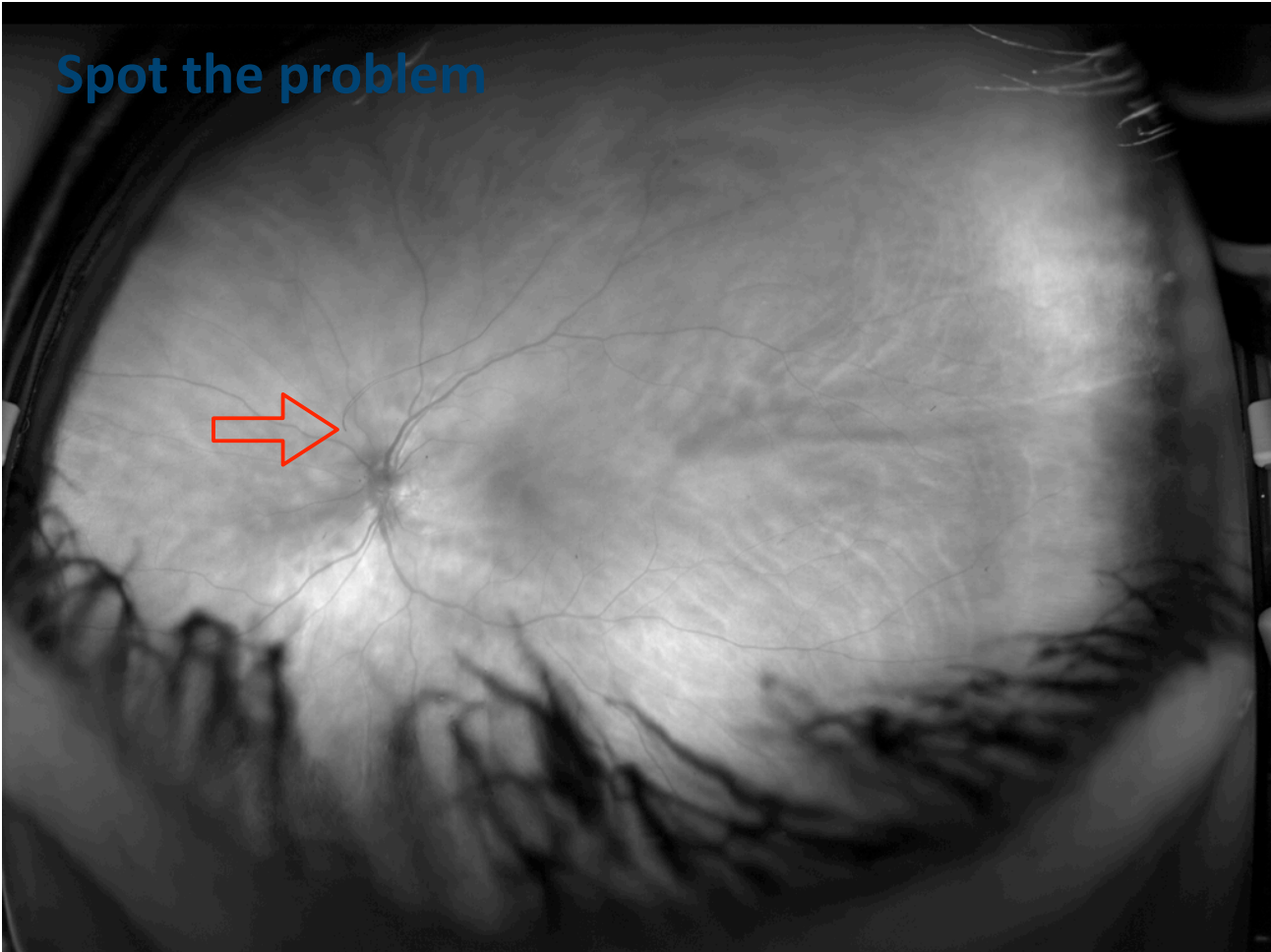
Sunday, 3 March 13

# Spot the problem

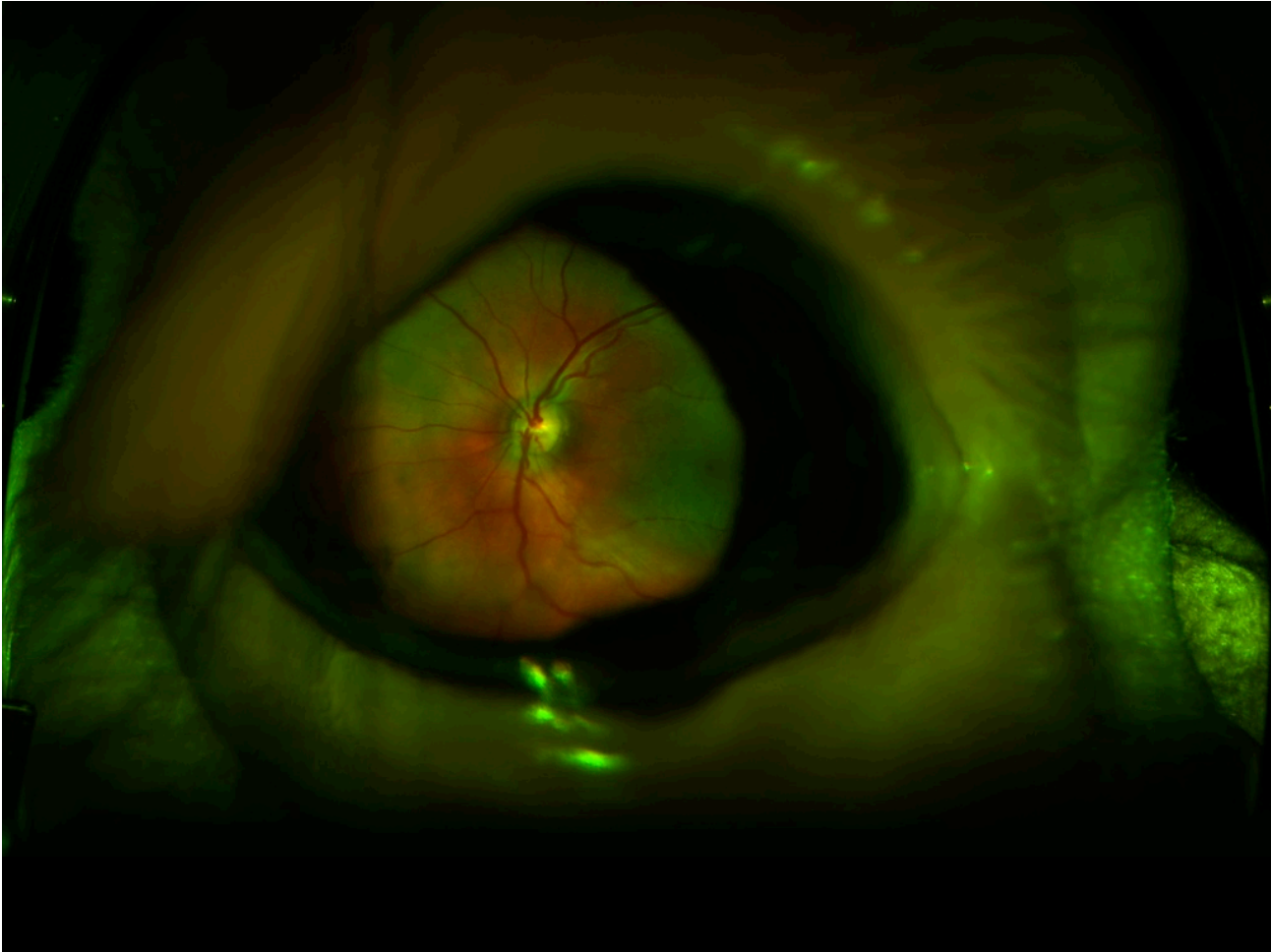


Sunday, 3 March 13

Spot the problem

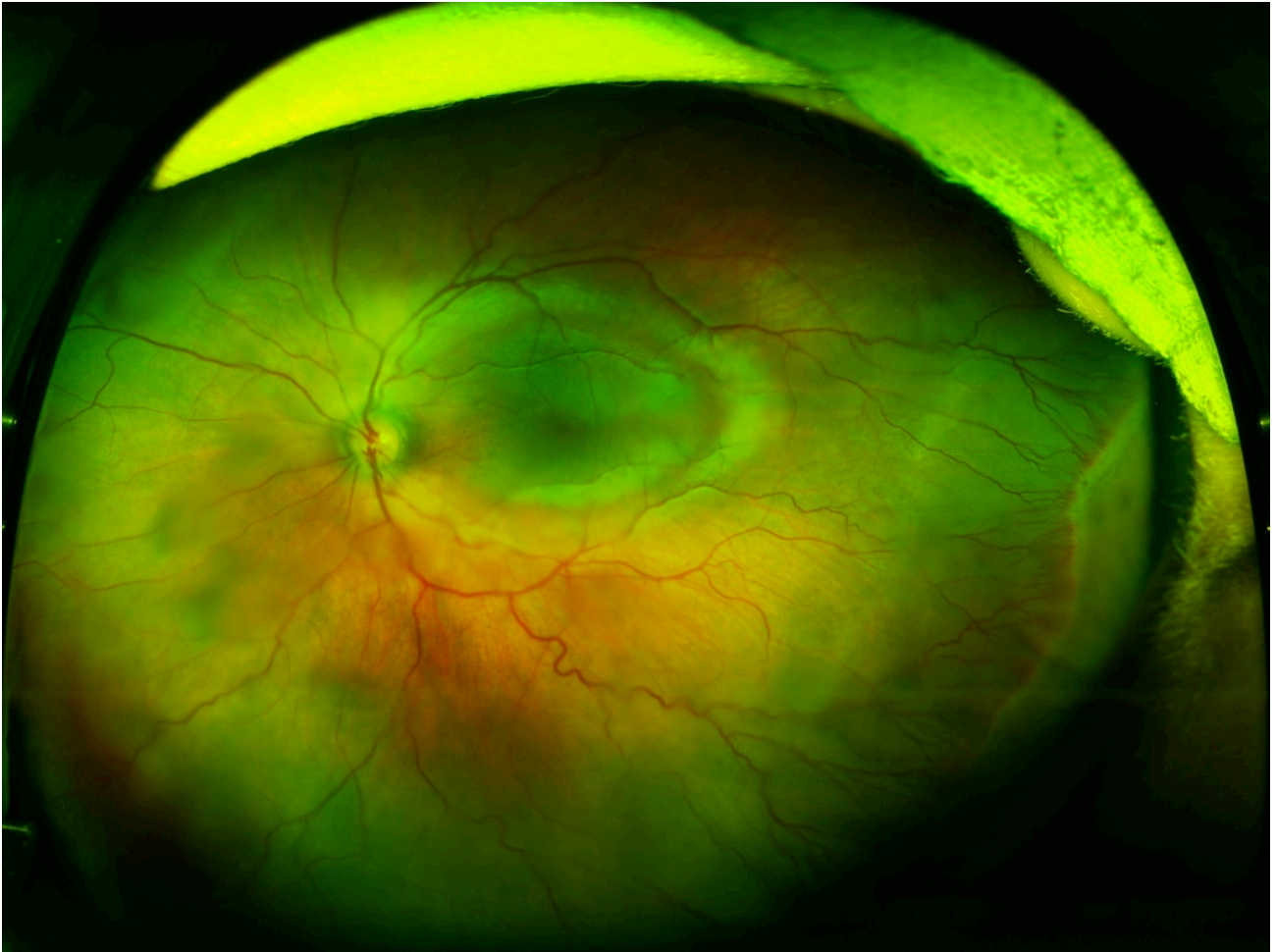


Sunday, 3 March 13



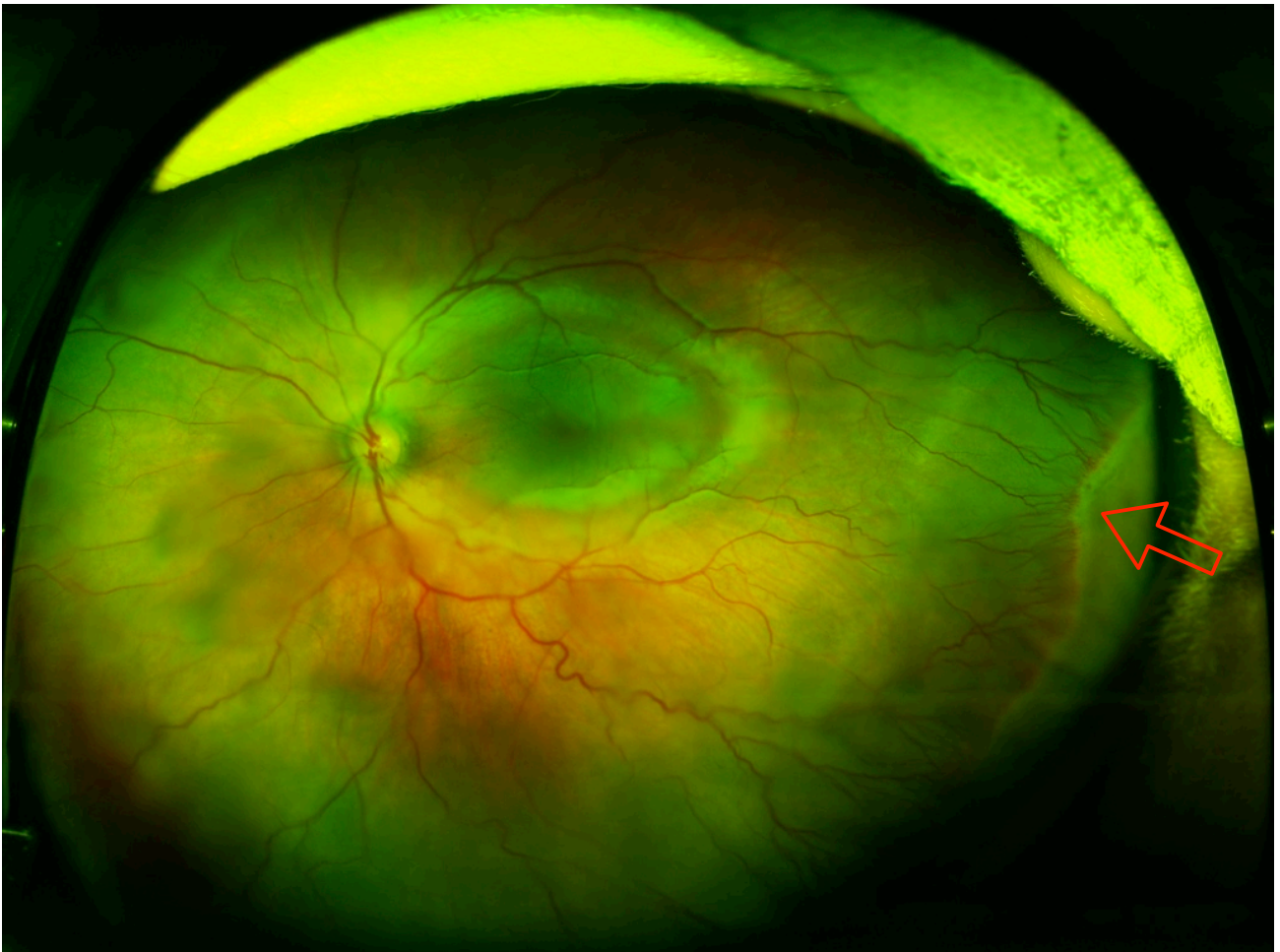
Sunday, 3 March 13





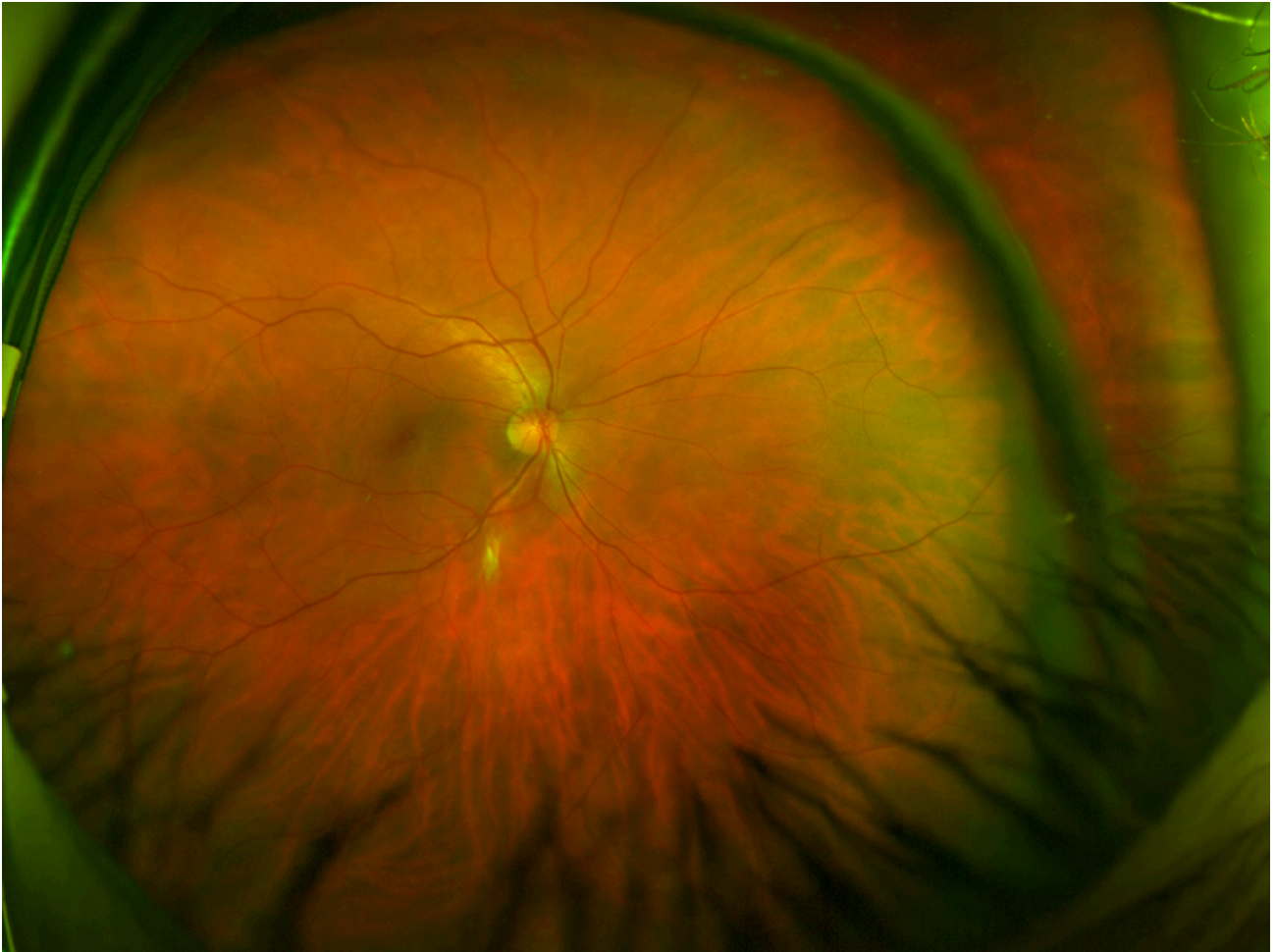
Sunday, 3 March 13

30



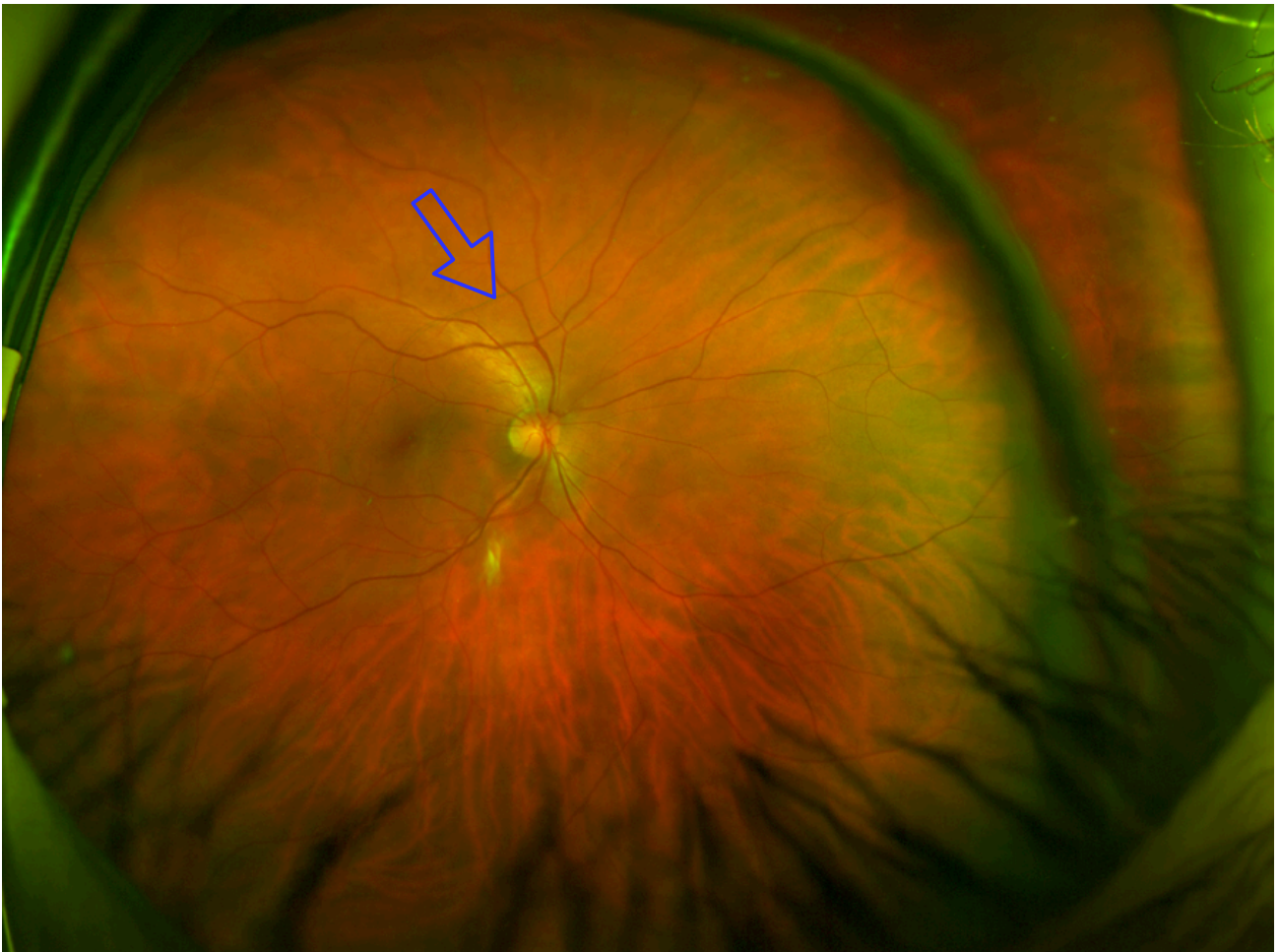Sunday, 3 March 13

30



Sunday, 3 March 13

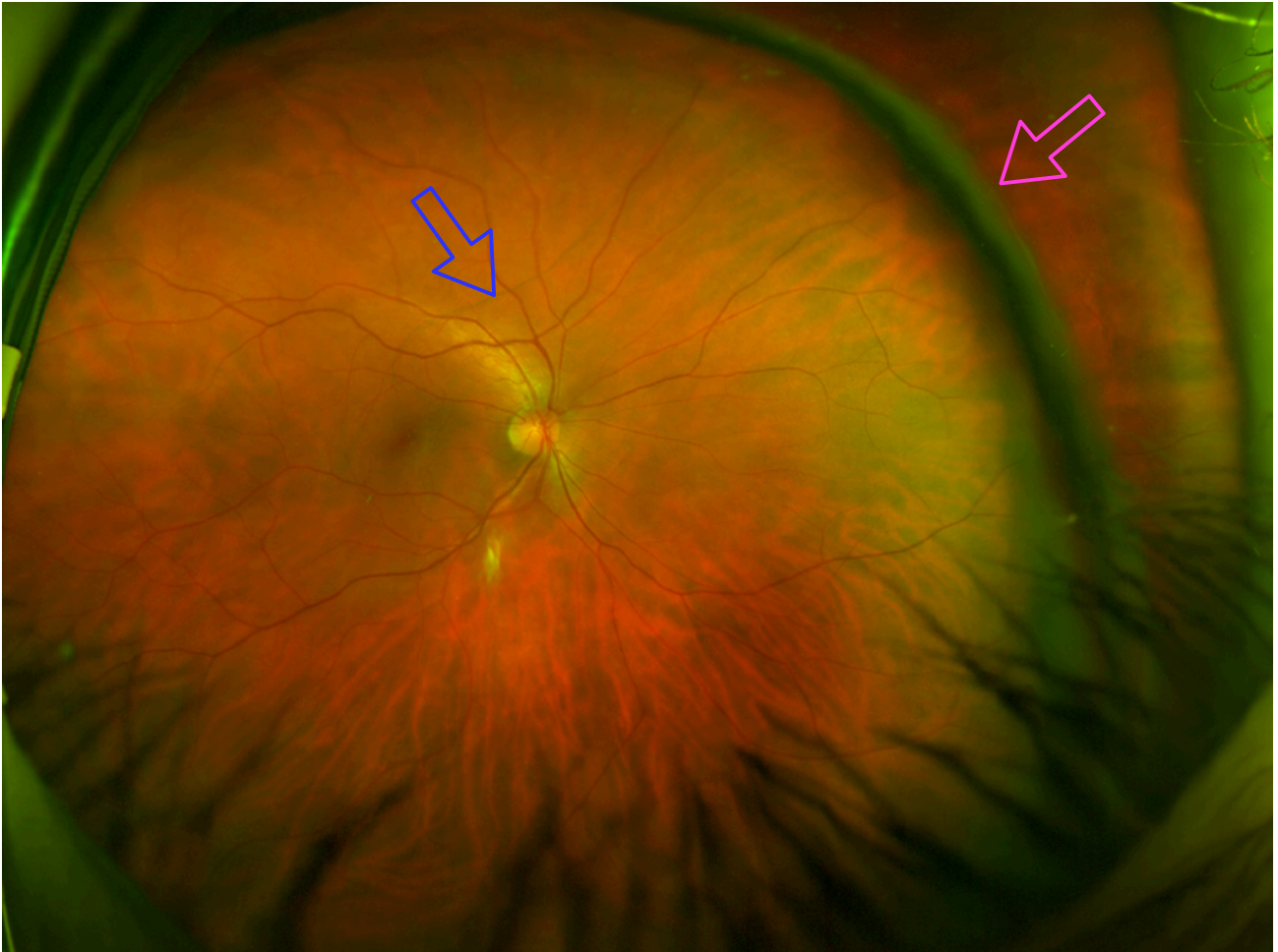
31



Sunday, 3 March 13

31





Sunday, 3 March 13

31

## Summary



Eye health care is a rapidly expanding market; its estimated growth is \$1,097m by 2016.

+


Retinal imaging requires constant technology innovation from physics and computer science.

=

Do work with us!

Sunday, 3 March 13

32



Thanks for  
listening

Contact me at

Optos plc  
Queensferry House  
Carnegie Business Campus  
Dunfermline  
Scotland KY11 8GR  
UK



T +44 (0)1383 843300  
D +44 (0)1383 843327  
F +44 (0)1383 843333  
E [jvanhemert@optos.com](mailto:jvanhemert@optos.com)  
W [www.optos.com](http://www.optos.com)

Dr Jano van Hemert  
Imaging Research Manager  
& Academic Liaison